

# The Enigmatic temporal pole: a review of findings on social and emotional processing

Ingrid R. Olson, Alan Plotzker and Youssef Ezzyat

Center for Cognitive Neuroscience, University of Pennsylvania, PA, USA

Correspondence to: Ingrid R. Olson, Center for Cognitive Neuroscience, University of Pennsylvania, 3720 Walnut Street, Room B5I, Philadelphia, PA 19104-6196, USA

E-mail: iolson@psych.upenn.edu

**The function of the anterior-most portion of the temporal lobes, the temporal pole, is not well understood. Anatomists have long considered it part of an extended limbic system based on its location posterior to the orbital frontal cortex and lateral to the amygdala, along with its tight connectivity to limbic and paralimbic regions. Here we review the literature in both non-human primates and humans to assess the temporal pole's putative role in social and emotional processing. Reviewed findings indicate that it has some role in both social and emotional processes, including face recognition and theory of mind, that goes beyond semantic memory. We propose that the temporal pole binds complex, highly processed perceptual inputs to visceral emotional responses. Because perceptual inputs remain segregated into dorsal (auditory), medial (olfactory) and ventral (visual) streams, the integration of emotion with perception is channel specific.**

**Keywords:** perirhinal cortex; anterior temporal lobe; ba 38; face processing; frontotemporal dementia

**Abbreviations:** FTD = frontal temporal dementia; TP = temporal pole

Received October 18, 2006. Revised January 15, 2007. Accepted February 26, 2007

## Introduction

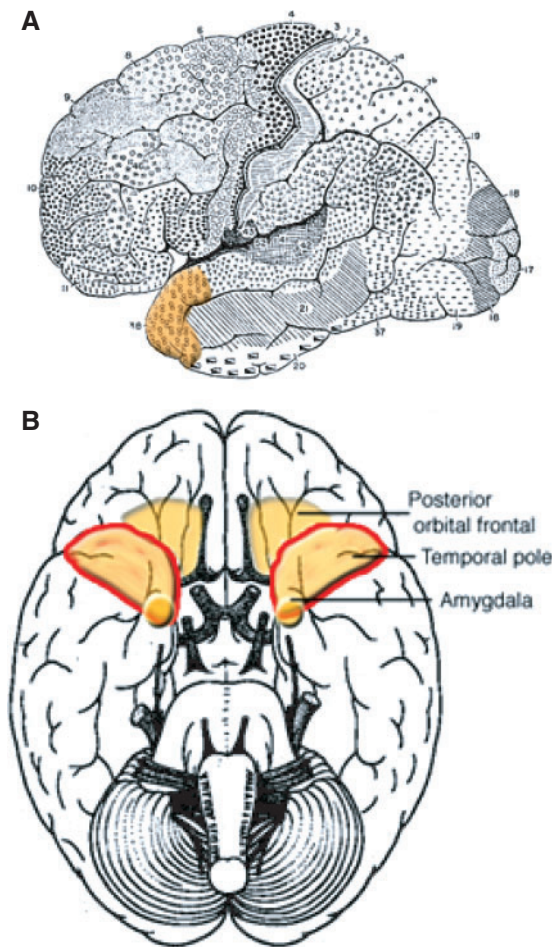
There has been considerable attention devoted to understanding the neural basis of social and emotional processing. The appeal of understanding these processes is driven partially by a need to understand disrupted socioemotional processing that lies at the heart of many psychiatric disorders. The two neuroanatomical regions most commonly linked to socioemotional processing are the amygdala and orbital portions of the prefrontal cortex. Less attention has been paid to a third region that lies between the orbital frontal cortex and the amygdala and receives and sends connections to both regions: the temporal pole (TP). Anatomists have referred to the TP as a paralimbic region based on its anatomical location and connectivity (Duvernoy, 1999; Mesulam, 2000). Whether the human TP has any social or emotional functions is not well-understood. An influential review of the fMRI literature noted that little was known about the functionality of this region and that few fMRI studies had reported activation there (Cabeza and Nyberg, 2000). This lack of knowledge is surprising given the fact that for decades, neurosurgeons have removed this area, along with diseased medial temporal lobe regions, in epilepsy resection surgery. Here we review the literature on the TP in hopes of filling an anatomical void in the literature on socioemotional

functions and the brain. We begin by discussing TP anatomy, and then move on to discuss Klüver–Bucy syndrome in monkeys and humans, disordered social and emotional processing in humans, face processing and theory of mind. We end with a theoretical discussion that synthesizes evidence on the particular role of the TP in socioemotional processing.

## Temporal pole anatomy

There are several excellent reviews of the anatomy of the anterior temporal lobe (Nakamura and Kubota, 1996; Stefanacci *et al.*, 1996; Gloor, 1997; Mesulam, 2000; Kondo *et al.*, 2003, 2005.) that we summarize here. The temporal pole, also referred to as BA 38, planum polare, area TG or the anterior aspect of perirhinal cortex, covers the anterior-most end of the temporal lobe, somewhat like a cap (Fig. 1). It is rostral to the perirhinal cortex. Some investigators have included the TP within their definition of the perirhinal cortex (Insausti *et al.*, 1987*a, b*; Suzuki and Amaral, 1994), which traditionally encompasses areas 35 and 36; however, it is more commonly considered a separate region (Insausti *et al.*, 1998).

The TP is highly interconnected with both the amygdala and orbital frontal cortex and is therefore often referred to



**Fig. 1** (A) Brodmann's depiction of the lateral surface of the human brain. The temporal pole (BA 38) is highlighted in orange. (B) A schematic diagram of the inferior surface of the human brain showing the anatomical relationship of the temporal pole to the posterior orbital frontal cortex and the amygdala (in reality the amygdala is buried under the cortex, but for the sake of illustration, has been depicted on the surface).

as a paralimbic region. A large white matter tract, the uncinate fasciculus, links the TP to prefrontal regions. Like other limbic regions, the TP receives and sends projections to the basal forebrain. It has been noted that the pattern of connectivity of the TP bears striking similarity to that of the amygdala. Dorsal portions of the TP project to the hypothalamus, a neuromodulatory region important for autonomic regulation of emotions. The tight connection between the TP and the hypothalamus may explain why electrical stimulation of the human TP produces changes in heart rate, respiration and blood pressure (Gloor *et al.*, 1982).

The TP, along with the temporal–parietal junction, has also been described as association cortex due to its unusual connectivity. It sends and receives connections to the three sensory systems represented in the temporal lobe. In the macaque, the dorsolateral TP receives projections from third-order auditory association cortex, the ventral TP

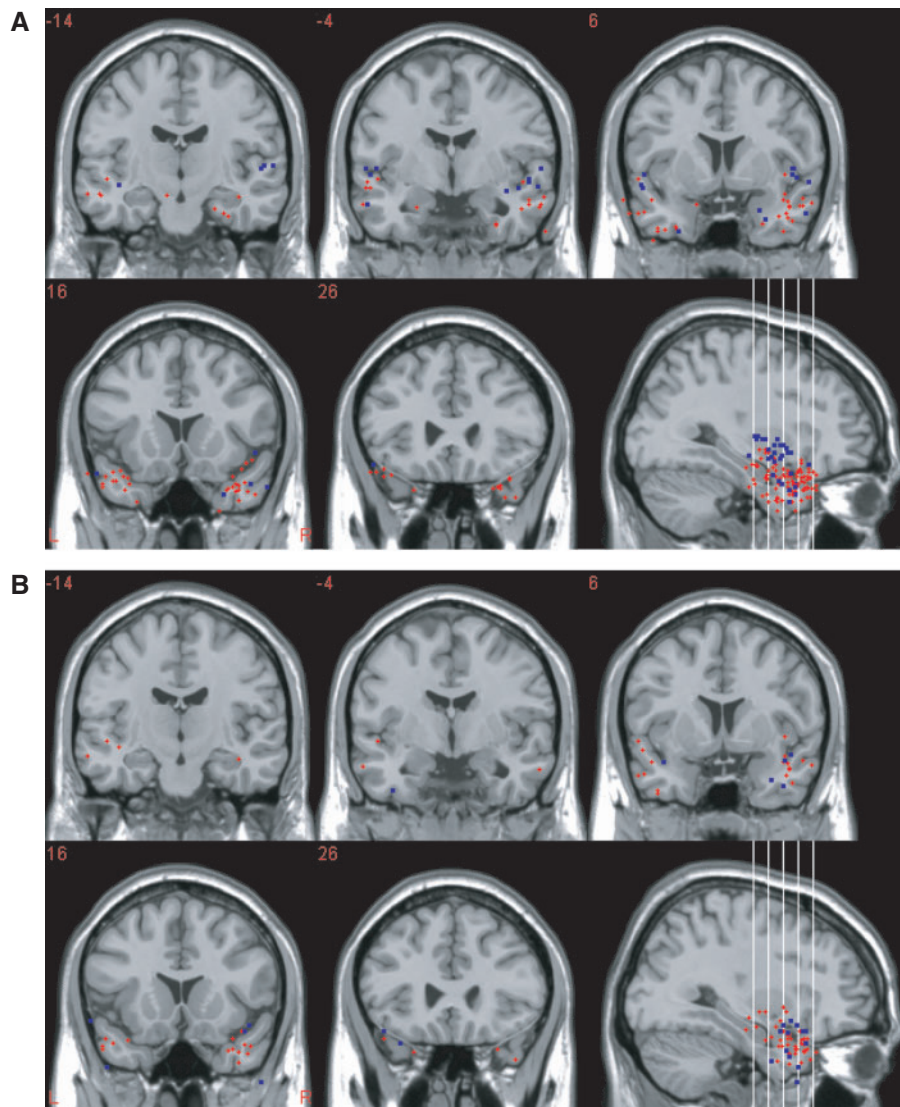
receives projections from extrastriate visual cortex in the inferior temporal lobe, and the medial TP receives projections from prepiriform olfactory cortex in medial aspects of the temporal lobe. Furthermore, the medial TP receives projections from the insula, which has an important role in gustation and awareness of internal physiological state (Critchley, 2004). Existing evidence from the macaque indicates that these processing streams do not converge, but rather, remain separate in the TP.

Because of a lack of anatomical data, it is unclear how the connectivity of the human TP compares to that of the macaque (Nakamura and Kubota, 1996). The language functions that are present in human temporal lobe, for example, make it possible that the connectivity of the human TP differs significantly from that found in non-human primates. As a first step in investigating this possibility, we reviewed neuroimaging studies that reported TP activations to a wide variety of tasks and stimuli and plotted the coordinates of anterior temporal lobe activations on a standard brain. We found that these activations tended to follow a dorsal/ventral segregation based upon whether the stimuli used were auditory or visual (Fig. 2A; methods found in Appendix A). This finding provides one piece of evidence that the human TP has a similar pattern of connectivity as the non-human primate TP. These findings also suggest that one function of the human TP is multimodal perceptual analysis. Its anatomical location and connectivity suggest that its function extends beyond perception to social and emotional processing, reviewed next.

### Temporal pole and Klüver–Bucy syndrome

One of the first hints that the TP was involved in socioemotional processing came from studies of Klüver–Bucy syndrome. The Klüver–Bucy syndrome in monkeys consists of tameness and diminished fear, hyperorality, hypersexuality, blunted affect, visual agnosia and social withdrawal (Klüver and Bucy, 1939; Kling *et al.*, 1993). Later studies found that lesions to the monkey TP, orbital frontal cortex or amygdala produce most, but not all, of the Klüver–Bucy symptoms (Horel *et al.*, 1975; Kling and Steklis, 1976; Kling *et al.*, 1993). The exception to this is ‘psychic blindness’ or visual agnosia, which is only produced when lesions include more posterior portions of the temporal lobe. Lesions to nearby areas, including inferior temporal cortex, superior temporal cortex, lateral surface of the frontal lobe and the anterior cingulate do not produce the striking social and emotional deficits of the Klüver–Bucy syndrome (Kling and Steklis, 1976; Kling *et al.*, 1993).

Perhaps the most interesting symptom of the Klüver–Bucy disorder is ‘social withdrawal’, a description that minimizes the scope of social impairment. Female monkeys with surgical lesions of the TP, excluding the amygdala, exhibit grossly abnormal social behaviour (Bucher *et al.*, 1970;



**Fig. 2** Centres of activation from fMRI and PET reporting anterior temporal lobe activations to **(A)** auditory or visual stimuli. Red dots show centres of activation reported for tasks that used clearly *visual* stimuli such as faces or houses, whereas blue dots show centres of activation reported for tasks that used *auditory* stimuli such as voices or music. **(B)** Emotion or theory of mind tasks. Red dots show centres of activation reported in *emotion* tasks, whereas blue dots show centres of activation reported in *theory of mind* tasks. Activation maps were created with MRIcro. Activation foci are shown in MNI space, in radiological convention (e.g. left is on the right). Studies used to create these images are listed in Appendices A and B.

Myers and Swett, 1970; Franzen and Myers, 1973; Myers, 1975; Kling and Steklis, 1976; Kling *et al.*, 1993). They do not produce appropriate social signals (vocal or facial) nor do they appear to recognize the social signals of peer monkeys. They showed little social interest in their peers, and at times are rejected from their social group. They become tame and show little aggression towards peer monkeys when provoked. Those with babies are neglectful and often violent towards them, causing consternation among other female monkeys. Some, but not all, of these social problems improve over time. Prefrontal and amygdala lesions lead to a similar pattern of behaviour, underscoring the tight coupling of the TP to these regions. In contrast, lesions to posterior temporal cortex

(TE or inferior temporal cortex) cause no social problems. (Table 1). These findings have been replicated in other species of monkey (Kling and Steklis, 1976), suggesting that there is evolutionary conservation of structure-function in the TP across primate species.

One explanation that has been offered for these findings is that prefrontal and TP regions are instrumental in supporting group social behaviours such as the tendency to band together to form societies, to participate in family life and to interact with others in the social group (Myers, 1969). However, there are many potential mental processes that sustain group social behaviours and no effort has been made to disentangle which of them are disrupted with TP damage. For instance, problems in recognizing the meaning

**Table 1** Summary of social and emotional behavioural change following bilateral ablation of orbital portions of the prefrontal cortex (PFC), temporal pole (TP), amygdala, inferior temporal cortex (IT) or anterior cingulate cortex (ACC) in various species of adult Old World monkeys

Behaviour	PFC	TP	Amygdala	IT	ACC
Klüver–Bucy	Partial	Partial	Full	None	None
Diminished fear	x	x	x		
Hyperorality	x	x	x		
Hypersexuality			x		
Blunted affect	x	x	x		x
Visual Agnosia				x	
Social disinterest	x	x	x		x
Decreased production of facial and vocal signals	x	x			x
Decreased aggression	x	x	x		
Rejection from social group	x	x	x		
Decreased social status	x	x	x		
Aberrant maternal behaviour	x	x	x		
Decreased grooming	x	x	x		

Note: It should be noted that Klüver–Bucy symptoms were only observed in laboratory monkeys while free-ranging monkeys tended to instead show severe social disinterest and withdrawal. Also, ablations in infant monkeys tend to cause less marked social deficits. Evidence derived from (Bucher *et al.*, 1970; Franzen and Myers, 1973; Kling and Steklis, 1976; Kling *et al.*, 1993; Miller *et al.*, 1995, 1997; Mychack *et al.*, 2001; Amaral *et al.*, 2003; Hadland *et al.*, 2003; Thompson *et al.*, 2003).

of social signals, in associating a social signal with the proper response or with an emotional reaction, in social interest, or in feeling emotions could all cause social deviance. Nevertheless, these findings constitute the first piece of evidence that the anterior temporal lobes, including the TP, play some important role in socioemotional processing.

### Temporal pole and clinical disorders of socioemotional regulation

TP dysfunction in humans has been associated with a host of socioemotional disorders. Klüver–Bucy syndrome can be observed after bilateral medial and anterior temporal lobe damage, as often occurs in herpes encephalitis (Lilly *et al.*, 1983). It has been observed after unilateral anterior temporal lobe damage (Ghika-Schmid *et al.*, 1995) and as a post-ictal temporal lobe epilepsy phenomenon (Anson and Kuhlman, 1993). It can also be observed in dementing diseases that affect the anterior-medial temporal lobes (Lilly *et al.*, 1983).

One of the most interesting deficits in socioemotional processing arises after atrophy to the right anterior temporal lobe, typically seen in the temporal variant of frontal temporal dementia (tv-FTD). FTD is a progressive disease characterized by a somewhat rapid degeneration of

**Table 2** A list of social and emotional deficits exhibited by monkeys with surgical ablation of bilateral TP, sparing the amygdala and analogous social and emotional deficits observed in humans with right lateralized tv-FTD

Monkeys with TP ablation	Humans with right tv-FTD
Loss of production of facial or vocal signalling	Loss of production of facial expressions; monotone voice
Loss of recognition of peer facial or vocal signals	Loss or poor recognition of facial expressions
Decreased interest in peers	Self-centred; loss of empathy; preoccupation with non-social stimuli (e.g. jigsaw puzzles)
Decreased aggression	Decreased affect
Rejection from social group	Avoided by family and friends
Decreased status in social hierarchy	Loss of extraversion and social dominance
Aberrant and neglectful maternal behaviour	—
Aberrant sexual behaviour	Hypo or hyper-sexuality
Hyperorality	Hyperorality
Decreased grooming	Decreased grooming; bizarre changes in dress

Note: Evidence derived from (Bucher *et al.*, 1970; Franzen and Myers, 1973; Kling and Steklis, 1976; Kling *et al.*, 1993; Miller *et al.*, 1995, 1997; Mychack *et al.*, 2001; Thompson *et al.*, 2003).

frontal and/or anterior temporal lobe tissue that can be left or right lateralized, and frontal or temporal localized. Temporal damage is most evident in polar regions, while more medial regions, such as the hippocampus, remain intact at early stages of the disease (Mummery *et al.*, 2000; Hodges, 2001). Patients with right, but not left, TP atrophy due to the tv-FTD exhibit changes in personality and socially appropriate behaviour (Thompson *et al.*, 2003). For instance, Gorno-Tempini and colleagues (2004) studied the cognitive, behavioural and anatomical features of patient JT who presented with marked changes in behaviour and personality. JT changed from an extraverted, highly empathic individual to a somewhat introverted and cold individual, lacking in empathy. She also lost much of her social dominance and became neurotic and demanding. Her indiscriminate eating behaviours provided the clearest evidence of her socially inappropriate behaviour. ‘If not controlled, [she] would eat floral table decorations and large quantities of butter, oil and jam by themselves’ (Gorno-Tempini *et al.*, 2004).

As this example illustrates, tv-FTD can at times cause partial or full-blown Klüver–Bucy syndrome. In fact, many of the deficits found in right lateralized tv-FTD mimic deficits observed in monkeys with surgical ablation of bilateral TP (Table 2). It has been reported that these patients have fixed facial expressions and have difficulties in posing facial expressions. Their abnormal expressions of affect make social interactions uncomfortable for both strangers and family members. Other affect-related problems include depression, irritability, apathy, emotional

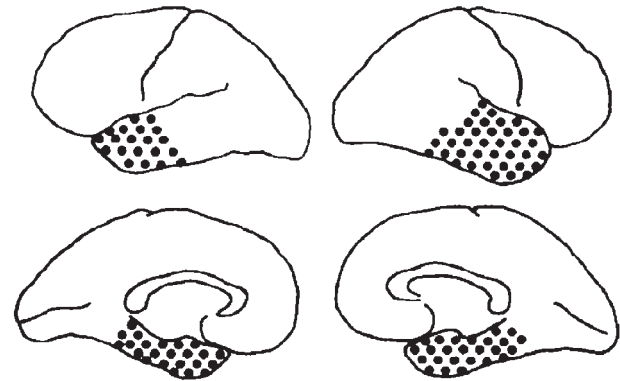
blunting and being ill at ease in company (Miller *et al.*, 1995; Miller *et al.*, 1997; Bozeat *et al.*, 2000; Mychack *et al.*, 2001; Thompson *et al.*, 2003). It is likely that some of the Klüver–Bucy symptoms resulting from bilateral TP damage are due to severing of white matter connections to other brain regions. Enhancement of oral tendencies has been produced experimentally by ablation of orbital frontal cortex (Butter *et al.*, 1969), and combined hyperphagia and hypersexuality has been observed in humans with thalamic lesions (Poeck and Pilleri, 1965). Both regions are highly interconnected with the TP (Mesulam, 2000).

TP damage can lead to unstable mood states. Damage due to trauma or surgical resection can lead to rapidly cycling bipolar disorder (Murai and Fujimoto, 2003) or rapidly cycling changes in clinical levels of depression, anxiety and irritation (Glosser *et al.*, 2000). The link between vasculating mood states and TP damage is also found in reports that traumatic or surgical damage to the anterior temporal lobe damage is associated with acquired bipolar disorder (Jorge *et al.*, 1993; Brooks and Hoblyn, 2005) and mania (Carran *et al.*, 2003). Last, there are intriguing links between anterior temporal lobe dysfunction and schizophrenia: several studies have reported that schizophrenics have smaller than normal temporal poles (Gur *et al.*, 2000; Kasai *et al.*, 2003; Crespo-Facorro *et al.*, 2004) and that TP neurons in post-mortem schizophrenic brain samples have abnormal microstructure (Ong and Garey, 1993). Schizophrenia-like psychoses, when present in epileptics, are most commonly observed when the seizure foci is in the left anterior temporal lobe (Glosser *et al.*, 2000).

### Temporal pole and face processing

The ability to recognize and identify other people is fundamental to human social processing. Numerous studies have identified a region of temporal cortex near the superior temporal sulcus in non-human primates that contains cells responsive to faces (Perrett *et al.*, 1985; Desimone, 1991; Gross, 1992) and an analogous region has been identified in inferior portions of the human temporal lobe (Kanwisher *et al.*, 1997). Fewer investigators are aware of evidence implicating the TP in face processing. There are four sources of evidence.

First, bilateral lesions to the anterior temporal lobes can cause a particular type of prosopagnosia termed ‘amnesic associative prosopagnosia’ by Damasio and colleagues (1990; see Fig. 3). Its name is based on the observation that it often occurs in the context of amnesia (Damasio *et al.*, 1990). Two distinguishing features of this type of prosopagnosia are that patients’ have preserved perception of faces, but impaired recognition of faces, and their deficit extends to non-face recognition cues like voice and gait. Bilateral damage and memory loss may not be necessary conditions for this disorder, as similar profiles of spared face perception and impaired face recognition have been



**Fig. 3** A schematic diagram of distribution of damage found in cases of amnesic associative prosopagnosia, also termed associative agnosia. The lesions shown in this diagram are bilateral and involve the anterior but not posterior temporal lobe (reprinted from Damasio *et al.* 1990, with permission).

reported for cases in which memory is intact and anterior temporal lobe damage is unilateral (Sergent and Signoret, 1992; Barton *et al.*, 2001, 2004).

Anterior temporal lobe resection surgery can also produce face processing deficits. Findings from this line of research have revealed interesting laterality differences. Left resection surgery can cause impaired proper naming abilities when shown photos of famous faces, while right resection surgery can cause impaired recognition of famous (Glosser *et al.*, 2003) or personally familiar (Tippett *et al.*, 2000) faces. Such deficits are observed whether naming people from a picture or a verbal description (Fukatsu *et al.*, 1999; Glosser *et al.*, 2003; Tsukiura *et al.*, 2003). Left TP resection can impair the ability to learn new face–name associations, whereas this is not true of right TP resections (Tsukiura *et al.*, 2003).

Second, temporal pole atrophy, as seen in tv-FTD, can cause severe impairments in naming famous faces. Thompson *et al.* (2003) found that 31 of the 47 FTD patients in their study had specific complaints of difficulty recalling people’s names. As with temporal lobe resection cases, name recognition difficulties are more commonly associated with left lateralized damage, while face recognition difficulties are more common after right-lateralized damage (Snowden *et al.*, 2004). This type of face processing deficit has been termed ‘progressive prosopagnosia’ (Barbarotto *et al.*, 1995; Evans *et al.*, 1995; Gentileschi *et al.*, 1999, 2001; Gainotti *et al.*, 2003; Joubert *et al.*, 2003; Snowden *et al.*, 2004).

Third, two studies in which face-related event-related potentials (ERPs) were recorded from electrodes implanted in the human brain reported that late face-specific ERPs (around 350 ms) were found in the ventral TP. These ERPs were later than face ERPs found in more posterior visual areas, and were right-lateralized whereas fusiform ERPs were bilateral (Allison *et al.*, 1994, 1999).

Fourth, a few neuroimaging studies have reported activations in the TP to faces. Some studies have reported

increased activations to familiar faces as compared to unfamiliar faces (Gorno-Tempini *et al.*, 1998; Leveroni *et al.*, 2000; Nakamura *et al.*, 2000; Grabowski *et al.*, 2001; Pourtois *et al.*, 2005; Rothstein *et al.*, 2005; Sergent *et al.*, 1992; Sugiura *et al.*, 2001) which concurs with lesion studies showing that the anterior temporal lobe is critical for person, but not face, recognition (Damasio *et al.*, 1990). Other studies have reported increased activations to emotional faces as compared to neutral faces (Phillips *et al.*, 1998; Blair *et al.*, 1999; Tsukiura *et al.*, 2003; Kim *et al.*, 2005).

In sum, evidence from numerous sources indicates that the anterior temporal lobe, though not critical for the perceptual analysis of faces, is critical for linking person-specific memories to perceptual representations of faces. Clearly, such a process is critical for adept social interactions and as such, may help to explain some of the deviant social behaviour exhibited by monkeys with TP lesions, reviewed earlier.

Is the TP selective for face processing? There are reports of patients with circumscribed TP damage that cannot recognize celebrities or name them from descriptions but have unimpaired recognition of landmarks (Gainotti *et al.*, 2003; Damasio *et al.*, 2004; Tranel, 2006). However, while face recognition difficulties are usually the earliest and most prominent symptom of TP damage due to progressive prosopagnosia (Barbarotto *et al.*, 1995; Evans *et al.*, 1995; Gentileschi *et al.*, 2001; Gainotti *et al.*, 2003; Thompson *et al.*, 2003; Snowden *et al.*, 2004), difficulties often extend to other modalities, such as recognizing people from their voice (Gentileschi *et al.*, 2001; Gainotti *et al.*, 2003), their name (Evans *et al.*, 1995; Snowden *et al.*, 2004) and even by their handwriting (Gentileschi *et al.*, 2001). In other words, unlike prosopagnosics with more posterior damage, progressive prosopagnosics lose all access to stored representations of person-related knowledge, a type of semantic memory.

Progressive prosopagnosics can exhibit other types of recognition problems too, such as an inability to recognize famous monuments and songs (Barbarotto *et al.*, 1995; Gentileschi *et al.*, 2001). Neuroimaging studies have largely confirmed these findings: two PET studies reported overlapping right temporal pole activations in response to viewing familiar faces and familiar buildings (Nakamura *et al.*, 2000; Grabowski *et al.*, 2001).

These findings can be reconciled if one takes into account the severity of impairment. It has been noted that TP patients with the worst person recognition scores also have difficulty with other non-person proper names (Hanley and Kay, 1998). A similar explanation can be applied to tv-FTD patients with person-identification deficits since patients with selective deficits identifying people (Evans *et al.*, 1995; Gainotti *et al.*, 2003) are nevertheless, quantitatively *better* at face-recognition than are patients whose impairments extend to other unique items (Barbarotto *et al.*, 1995; Gentileschi *et al.*, 2001).

This finding suggests that the TP is necessary, but not specialized, for person recognition. Person recognition may simply be more sensitive to neuronal loss in the TP than are other types of subordinate-level recognition.

### Thinking about others: theory of mind

Theory of mind is the ability to infer the desires, intentions or beliefs of others. There are several ways to study this, although one of the most common ways is to read short stories or view cartoons that depict a scenario in which another's thoughts or beliefs must be inferred. Many neuroimaging studies (Table 3), using different tasks and stimuli, have implicated the temporal poles in theory of mind (see Fig. 2B for activations patterns) (Fletcher *et al.*, 1995; Goel *et al.*, 1995; Baron-Cohen *et al.*, 1999; Brunet *et al.*, 2000; Gallagher *et al.*, 2000; McCabe *et al.*, 2001; Vogeley *et al.*, 2001; Berthoz *et al.*, 2002; Ferstl and von Cramon, 2002; Gallagher *et al.*, 2002; Calarge *et al.*, 2003; Walter *et al.*, 2004; Mitchell *et al.*, 2006; Saxe and Powell, 2006). An implicit theory of mind task in which subjects viewed geometric shapes that moved with intentionality and cause (Heider and Simmel, 1944) has been used by several groups who also found activations in the temporal pole (Castelli *et al.*, 2000; Schultz *et al.*, 2003; German *et al.*, 2004; Iacoboni *et al.*, 2004; Ohnishi *et al.*, 2004).

Other tasks that require subjects to think about others' thoughts and emotions have produced TP activations. One study reported TP activations when subjects were asked to detect deception (Grezes *et al.*, 2004), while another study reported TP activations when subjects were asked to make moral decisions (Moll *et al.*, 2002b; Heekeren *et al.*, 2003). At least three studies have reported activations in the temporal pole while inferring the emotional state of others (Farrow *et al.*, 2001; Carr *et al.*, 2003; Vollm *et al.*, 2006). TP activations correlate with 'personal distress scores', a measure of how much you feel another's negative emotions, in normal populations of college students (Moriguchi *et al.*, 2006). Interestingly, Vollm and colleagues (2006) found that activation clusters for a theory of mind task and an empathy task overlapped in the TP, leading them to suggest that this region functions generally in making inferences about the mental state of others. These findings have led some researchers to conclude that the temporal poles are a critical part of the 'mentalizing' brain (Frith, 2001; Frith and Frith, 2003).

Neuropsychological studies have provided mixed results for this theory. One of the only neuropsychological studies that examined this topic tested a large sample of patients with various degrees of amygdala damage. The results showed that adult-onset amygdala damage did not generally impair theory of mind performance and importantly, that extra-amygdala damage to the TP did not compromise theory of mind abilities (Shaw *et al.*, 2004). This finding casts some doubt on the idea that the TP (or the amygdala) is critical for theory of mind in adults, although it should

**Table 3** A list of neuroimaging studies of mentalizing or theory of mind

	Stimuli					TP activation?	
	Faces	Movies	Comics	Game	Stories	Yes	No
Berthoz (2002)					✓	✓	
Blakemore (2003)		✓					
Brunet (2000)			✓				✓
Calarge (2003)					✓	✓	
Calder (2002)	✓						✓
Castelli (2000)	✓					✓	
Ferstl (2002)					✓	✓	
Fletcher (1995)					✓	✓	
Gallagher (2000)					✓	✓	
Gallagher (2002)				✓			✓
German (2004)		✓					✓
Grezes (2004)		✓				✓	
Iacoboni (2004)		✓				✓	
Mitchell (2006)					✓	✓	
Moll (2002)					✓	✓	
Ohnishi (2004)		✓				✓	
Rilling (2004)				✓			✓
Saxe (2006)					✓	✓	
Schultz (2003)		✓				✓	
Vogley (2001)					✓	✓	
Walter (2004)			✓			✓	

Note: Studies that used head coils are excluded from the list. The type of visual stimulus is listed in the middle columns, and the far right columns indicate whether or not temporal pole activations were observed.

be noted that the TP was only partially damaged in all cases. In contrast, evidence from tv-FTD lends support to the theory that the TP is critical for theory of mind. A common complaint among family members of patients with tv-FTD is that the patient exhibits a pervasive lack of empathy (Mychack *et al.*, 2001). Recent findings show that patients with FTD have lower levels of empathy than controls or patients with Alzheimer's disease (Rankin *et al.*, 2006) and that tv-FTD is associated with disruption of both emotional empathy and perspective-taking, one measure of cognitive empathy that is similar to theory of mind (Rankin *et al.*, 2006).

Various ideas have been offered for how to interpret these findings. One suggestion is that TP activations in theory of mind tasks reflect retrieval of semantic memory scripts (Frith and Frith, 2003); however, there is no reason to think that the semantic memory demands of theory of mind tasks are any different from the semantic memory demands of non-theory of mind control tasks. This is especially true of theory of mind tasks that used geometric shapes that move with intentionality and cause (Castelli *et al.*, 2000; Schultz *et al.*, 2003). Another interpretation is that the TP has some role in encoding personal memories (Nakamura and Kubota, 1995) and thus in theory of mind tasks, the TP utilizes personal memories to comprehend the state of mind of others (Moriguchi *et al.*, 2006). Last, it is possible that theory of mind tasks taps person recognition functions of the TP, although this idea does not account for the fact that most studies of face processing and gaze

processing have failed to report activations in the TP. Further consideration of this topic is found in the section titled 'Negative Findings'.

### The temporal pole in socioemotional processing: theoretical considerations

The studies reviewed in the previous sections provide convincing evidence that the TP plays some role in socioemotional processing. We now turn to the problem of defining what exactly that role is. We have already provided some analysis of the function of this region for face processing and theory of mind processing; here we offer a more general framework for understanding the social and emotional functionality of the TP. It has been suggested that the TP is part of a system that modulates visceral emotional functions in response to emotionally evocative perceptual stimuli, based on its anatomical connectivity (Kondo *et al.*, 2003, 2005). We further suggest that this system is reactivated when emotions are perceived or imagined and that mnemonic functions of this region allow for storage of perception–emotion linkages, forming the basis of personal semantic memory.

The macaque dorsal TP receives input from auditory association areas (Kondo *et al.*, 2003), cells in this region are known to respond to complex auditory stimuli (Kondo *et al.*, 2003; Poremba *et al.*, 2003), and as shown in Fig. 2A, auditory stimuli tend to activate dorsal portions of the anterior temporal lobe, with a left-lateralization bias.

If our hypothesis is true, it is possible that dorsal portions of the TP are responsible for coupling visceral emotional responses with representations of complex auditory stimuli. A case study hints at this possibility. It was reported that in the year after having left temporal lobectomy surgery, a young man exhibited dramatic changes in musical taste. 'He found that the [rock] music he used to listen to before the operation sounded "too hard, too fast, and too violent". He now had a preference for Celtic or Corsican polyphonic singing' and '...he now had difficulty staying with his old friends, since he could no longer share his musical preferences and hence his topics of discussion' (Sellal *et al.*, 2003). Thus loss of the left TP led to changes in emotional reactions to complex auditory stimuli and, subsequently, to changes in social affiliation. At least two neuroimaging studies have reported activations in this region to aversive sounds such as a baby crying (Lorberbaum *et al.*, 2002) or woman screaming (Royet *et al.*, 2000). Many neuroimaging studies have reported activations in this region to pleasant sounds such as complex music (Brown *et al.*, 2004; Platel, 2005; Satoh *et al.*, 2006) and laughter (Royet *et al.*, 2000).

In contrast, the macaque ventral TP receives inputs from visual association areas in the inferior temporal lobe (Kondo *et al.*, 2003) and is thought to be the endpoint of visual processing. Cells in the macaque TP respond most strongly to complex visual stimuli (Nakamura *et al.*, 1994; Nakamura and Kubota, 1996) and as shown in Fig. 2A, ventral portions of the human TP tend to respond to complex visual stimuli such as faces, cartoons and photographs of houses in neuroimaging tasks. Our hypothesis would predict that ventral portions of the TP couple visceral emotional responses to complex visual stimuli. Sellal (2003) reported that the lobectomy patient who experienced a radical change in musical tastes, also exhibited changes in pictorial preferences, a finding that has also been noted in the FTD literature (Miller *et al.*, 1998, 2000). Some PET and fMRI studies have used visual stimuli to evoke negative emotions and found activations in the TP to emotions such as sadness (Lane *et al.*, 1997b; Blair *et al.*, 1999; Eugene *et al.*, 2003; Levesque *et al.*, 2003), anxiety (Reiman *et al.*, 1989; Chua *et al.*, 1999; Kimbrell *et al.*, 1999), anger (Dougherty *et al.*, 1999; Kimbrell *et al.*, 1999; Damasio *et al.*, 2000), fear (Phillips *et al.*, 1998) and disgust (Lane *et al.*, 1997b; Phillips *et al.*, 1998). TP activations have also been associated with various positive emotions such as humour generated by cartoons (Mobbs *et al.*, 2003), sexual arousal induced by pornography (Redoute *et al.*, 2000; Beauregard *et al.*, 2001) or maternal feeling generated by watching a video of one's own infant (Ranote *et al.*, 2004).

Medial aspects of the macaque TP receive olfactory and gustatory inputs (Mesulam, 2000). Few studies have examined emotional processing of these stimuli in humans; there is some evidence from PET that the TP is responsive to valenced olfactory stimuli (Royet *et al.*, 2000).

One prediction of our hypothesis is that damage to the TP should cause a decoupling of high-level perception with visceral emotional experience. One study reported that a patient who underwent right temporal lobectomy lost all emotional attachments to his family members, although recognition of them remained intact (Lipson *et al.*, 2003). It has also been reported that a patient with a large right TP lesion extending posteriorly in the fusiform gyrus believed that her family had been replaced by imposters (Hudson and Grace, 2000), possibly due to a decoupling between neural face recognition systems and emotion systems (Hirstein and Ramachandran, 1997). Last, as noted earlier, monkeys with bilateral TP ablations lose normal emotional attachments to their infants and to peer monkeys (Bucher *et al.*, 1970; Kling and Steklis, 1976).

A question that arises is how does the TP differ functionally from the amygdala or the orbital frontal cortex? One strong possibility is that within the TP there is still sensory-limbic segregation of auditory, visual and olfactory channels that is not present in the amygdala or orbital frontal cortex (Kling and Steklis, 1976). This raises the possibility of modality-specific socioemotional disorders. Resection for temporal lobe epilepsy would cause unilateral damage to the entire TP. However, trauma, stroke or tumour could cause focal damage to only one sensory-limbic channel.

## Negative findings

There is a growing neuroimaging literature on socio-emotional processing. Most of these studies report amygdala and various frontal activations, but do not report TP activations. One difficulty in interpreting null results is that the lack of activations could either mean that the TP is insensitive to the task or stimulus or it could simply reflect the fact that air-tissue inhomogeneities, a problem in imaging all neural regions near the sinuses, have diminished the BOLD signal to such a degree that no activations are visible (Devlin *et al.*, 2000). An additional problem is that the existing literature on socioemotional processing has at times emphasized activations in the amygdala and frontal regions but downplayed activations in regions such as the TP. TP activations are frequently listed in tables but are not discussed (Beauregard *et al.*, 2001; Moll *et al.*, 2002b), or are lumped into ill-defined anatomical categories such as 'periamygdaloid' or 'paralimbic cortex' (Miller *et al.*, 2005; Dapretto *et al.*, 2006), which tends to obscure the reader's ability to discern TP activations.

These issues aside, it is interesting to note that TP activations are frequently observed in complex emotional tasks such as theory of mind tasks, but less frequently observed in simpler emotional tasks, such as emotional face perception or gaze perception tasks. Table 3 lists neuroimaging studies of theory of mind and shows that the TP is activated by a variety of stimuli: movies, comics, sentences and stories. The instances in which it is not

activated are informative. For instance no activations were observed in one study that used animated sequences that lacked a social component (Blakemore *et al.*, 2003), whereas animated sequences that contain a social component are overwhelmingly associated with TP activations (Castelli *et al.*, 2000; Schultz *et al.*, 2003; German *et al.*, 2004; Grezes *et al.*, 2004; Iacoboni *et al.*, 2004; Ohnishi *et al.*, 2004). Although a social component appears to be necessary to activate this region, it is not sufficient. Two studies in which comparisons were made between conditions in which subjects thought they were playing computer games against humans versus computers did not report TP activations (Gallagher *et al.*, 2002; Rilling *et al.*, 2004) nor have studies that have examined various aspects of eye gaze (Calder *et al.*, 2002).

The findings to date from neuroimaging studies of theory of mind suggest that the TP is sensitive to stimuli that tell a story. More specifically, the TP is sensitive to stimuli with socially important narratives, either in the form of a film strip, a comic strip or a story, and to tasks that require one to analyse other agent's emotions, intentions or beliefs. It is somewhat insensitive to stimuli with non-social narratives and to tasks that require simple perceptual-level analyses such as direction of gaze.

As mentioned earlier, bilateral removal of monkey TP disrupts the ability to recognize, interpret and react to a host of social signals (Kling and Steklis, 1976). This region contains cells that are responsive to complex visual and auditory stimuli (Nakamura and Kubota, 1996; Kondo *et al.*, 2003, 2005). These cells are critical for both high-level perception and perceptual memory because they demonstrate certain mnemonic properties (Nakamura and Kubota, 1996). One can therefore interpret the neuroimaging findings from theory of mind tasks as reflecting the linkage of recognized social cues to emotional interpretations and reactions. Unlike regions such as the superior temporal sulcus, which is sensitive to biological motion and direction of gaze (Puce and Perrett, 2003), the TP is sensitive to complex social stimuli with a narrative or script.

### Laterality differences

There is some evidence pointing towards interesting laterality differences in the TP. The right anterior temporal lobe appears to be associated with emotion and socially relevant memory. Right lateralized temporal lobe epilepsy is associated with a higher prevalence (83 versus 69%) of axis-I psychiatric disorders such as major depression and anxiety disorders as compared to left lateralized temporal lobe epilepsy (Glosser *et al.*, 2000). Atrophy of the right anterior temporal lobe in tv-FTD is associated with changes in mood (e.g. emotional blunting, depression, irritability, apathy), personality (e.g. from extraverted to introverted; sudden acquisition of peculiar new interests and hobbies) and in socially appropriate behaviour (Miller *et al.*, 1995, 1997; Bozeat *et al.*, 2000; Mychack *et al.*, 2001;

Thompson *et al.*, 2003). The degree to which these social problems reflect temporal or frontal damage is difficult to estimate since only macroscopic tissue loss is evident on MRIs.

It has been suggested that the right TP is the storehouse (Nakamura *et al.*, 2000), or cite of recollection (Markowitsch, 1995) of personal, episodic memories. This hypothesis is based on findings showing that resection of the right TP can diminish that ability to recognize, or recall any information about famous or personally familiar faces (Fukatsu *et al.*, 1999; Tippett *et al.*, 2000; Glosser *et al.*, 2003; Tsukiura *et al.*, 2003). This deficit may reflect in part, a difficulty in recalling personal memories relevant to the test faces. A unique patient, RFR, after suffering damage to mostly the right and to a minor extent the left anterior temporal lobe, could generate names and information about family friends, but was unable to give any information about personal interactions or episodes pertaining to the same family friends (McCarthy and Warrington, 1992).

In contrast, the left anterior temporal lobe is more closely associated with semantic memory. Left resection surgery leaves the ability to generate information about people intact, but causes proper naming abilities (Glosser *et al.*, 2003) and face-name associative learning (Tsukiura *et al.*, 2003) to plummet. Similarly, left anterior temporal lobe atrophy in tv-FTD is largely associated with semantic memory impairments (Snowden *et al.*, 2004). A review of retrograde amnesia cases found that left frontal/anterior temporal lobe damage usually led to loss of previously learned semantic memory, but left episodic memory intact (Markowitsch, 1995).

These findings raise the possibility that the right TP functions to link high-level sensory representations with emotional responses and social memory. The left TP functions to link high-level sensory representations, such as a face, with semantic information. However, more research is needed to clarify whether such a dissociation truly exists.

### Social or emotional processing?

Any disruption of emotional processing will cause changes in social behaviour because normal social behaviour is predicated on emotion. Do the social deficits that are associated with TP damage go beyond emotional dysfunction? It is plausible that some of the social deficits reported in monkeys with bilateral TP lesions are actually due to a decoupling of emotions with perception and behaviour. For instance, the finding that mother monkeys forcibly reject their infants after TP damage may be due to the fact that the sight, smell and sound of their infant no longer arouses protective, nurturing maternal emotions, so the infant is rejected. Likewise, the failure to make and respond appropriately to social signals may be due to the fact that social interactions of any sort fail to elicit positive, rewarding emotions after TP damage. It is even possible

that learned associations between perception and emotion are lost after TP damage, leading to inappropriate behaviour toward other monkeys.

Many of the strange social behaviours associated with tv-FTD can also be viewed as a decoupling between perception and emotion. It has been reported that such patients often become introverted and cold (Rankin *et al.*, 2003), possibly reflecting a failure to derive pleasure or reward from social interactions. And as mentioned earlier, theory of mind tasks may rely on emotional processing to derive a social judgement.

However, there are some findings that do not neatly fit into the emotion category. First, there is a great deal of evidence pointing towards a role of the right TP in face memory and autobiographical memory, while the left TP has some role in personal semantic memory. These types of memory can be construed as types of social memory, and cannot be easily construed as fundamentally emotion-based. Second, the reviewed findings on neuroimaging studies of theory of mind indicate that TP activations are most frequently seen with tasks and stimuli in which there is some sort of social narrative, while simpler emotional stimuli rarely evoke TP activations. In sum, the data clearly indicate that the TP is involved in emotional processing while newer findings indicate that it may also have some role in social processing that goes beyond emotional processing.

### Summary of social and emotional findings

The findings reviewed here support the functional role of the TP as a paralimbic region. The monkey lesion literature showed that bilateral TP lesions cause abnormal social and emotional processing. In humans, atrophy of the right TP and surrounding regions, found in right temporal variant of frontal temporal dementia, is distinguished by profound changes to personality, emotional regulation and social behaviour that mimic the deficits observed in monkeys with TP lesions. Other findings indicate that the TP is critical for aspects of face processing, specifically, recognition from auditory or visual cues. The former process may be linked to ventral aspects, the latter to dorsal aspects. Last, the neuroimaging literature links the TP to emotional processing of auditory, olfactory and visual stimuli and to mentalizing, or theory of mind.

We propose that a general function of the TP is to couple emotional responses to highly processed sensory stimuli. The mnemonic functions of this region allow for storage of perception–emotion linkages, forming the basis of personal semantic memory.

This hypothesis acknowledges that the TP is involved in high-level recognition as the end point of the auditory and visual ‘what’ streams, but also proposes that the functionality of this region extends beyond linking perceptual and mnemonic representations for recognition to include linkages with visceral emotional responses. Our review of

the literature suggests that sensory streams are relatively separate in the human TP, suggesting that sensory–limbic binding is not integrated across sensory modality in this region.

Unfortunately, the paucity of systematic investigations of this region leaves many questions unanswered. For instance, we showed that there is a dorsal/ventral segregation of auditory and visual processing in the anterior temporal lobe. Is there any anatomical segregation of different types of emotional responses in this region? Also, a number of studies have found that ablations of the monkey orbital frontal cortex, the TP, and the amygdala cause a similar constellation of socioemotional deficits (Table 1). How do the roles of these regions differ in regards to social and emotional processing? There is evidence that the orbital frontal cortex and TP share many cytoarchitectural and response characteristics, as well as a close geographic relationship with neighbouring limbic structures (Kling and Steklis, 1976). Several findings, point towards a role for the anterior temporal lobes in emotional stability but more systematic studies are needed to flesh out its particular function. Emotion researchers have paid little attention to this region, with the bulk of interest centred on the nearby amygdala. We hope that the evidence reviewed here will spark future investigations of the social and emotional functions of this region.

### Acknowledgements

We would like to thank the laboratories of Anjan Chatterjee and Geoff Aguirre for helpful discussion. Funding to pay the open access charges provided by startup-funds from the University of Pennsylvania to Ingrid Olson.

### References

- Allison T, McCarthy G, Nobre A, Puce A, Belger A. Human extrastriate visual cortex and the perception of faces, words, numbers, and colors. *Cereb Cortex* 1994; 4: 544–54.
- Allison T, Puce A, Spencer DD, McCarthy G. Electrophysiological studies of human face perception. I: potentials generated in occipitotemporal cortex by face and non-face stimuli. *Cereb Cortex* 1999; 9: 415–30.
- Amaral DG, Bauman MD, Mills Schumann C. The amygdala and autism: implications from non-human primate studies. *Genes Brain Behav* 2003; 2: 295–302.
- Anson JA, Kuhlman DT. Post-ictal Klüver-Bucy syndrome after temporal lobectomy. *J Neurol Neurosurg Psychiatry* 1993; 56: 311–3.
- Barbarotto R, Capitani E, Spinnler H, Trivelli C. Slowly progressive semantic impairment with category specificity. *Neurocase* 1995; 1: 107–19.
- Baron-Cohen S, Ring HA, Wheelwright S, Bullmore ET, Brammer MJ, Simmons A, *et al.* Social intelligence in the normal and autistic brain: an fMRI study. *Eur J Neurosci* 1999; 11: 1891–8.
- Barton JJS, Cherkasova MV, Hefter R. Covert priming effect of faces in prosopagnosia. *Neurology* 2004; 63: 2062–8.
- Barton JJS, Cherkasova MV, O'Connor M. Covert recognition in acquired and developmental prosopagnosia. *Neurology* 2001; 57: 1161–8.
- Beauregard M, Levesque J, Bourgouin P. Neural correlates of the conscious self-regulation of emotion. *J Neurosci* 2001; 21: 1–6.

- Berthoz S, Armony JL, Blair RJR, Dolan RJ. An fMRI study of intentional and unintentional (embarrassing) violations of social norms. *Brain* 2002; 125: 1696–708.
- Blair RJR, Morris JS, Frith CD, Perrett DI, Dolan R. Dissociable neural responses to facial expressions of sadness and anger. *Brain* 1999; 122: 883–93.
- Blakemore SJ, Sarfati Y, Bazin N, Decety J. The detection of intentional contingencies in simple animations in patients with delusions of persecution. *Psychol Med* 2003; 33: 1433–41.
- Bozeat S, Gregory CA, Lambon Ralph MA, Hodges DA. Which neuropsychiatric and behavioural features distinguish frontal and temporal variants of frontotemporal dementia from Alzheimer's disease? *J Neurol Neurosurg Psychiatry* 2000; 69: 178–86.
- Brooks JO, Hoblyn J. Secondary mania in older adults. *Am J Psychiatry* 2005; 162: 2033–8.
- Brown S, Martinez MJ, Hodges DA, Fox PT, Parsons LM. The song system of the human brain. *Cogn Brain Res* 2004; 20: 363–75.
- Brown S, Parsons LM, Martinez MJ, Hodges DA, Krumhansl C, Xiong J, et al. The neural bases of producing, improvising, and perceiving music and language. *J Cogn Neurosci*.
- Brunet E, Sarfati Y, Hardy-Bayle MC, Decety J. A PET investigation of the attribution of intentions with a nonverbal task. *Neuroimage* 2000; 11: 157–66.
- Bucher K, Myers RE, Southwick C. Anterior temporal cortex and maternal behavior in monkey. *Neurology* 1970; 20: 415.
- Bukach CM, Bub DN, Gauthier I, Tarr MJ. Perceptual expertise effects are not all or none: spatially limited perceptual expertise for faces in a case of prosopagnosia. *J Cogn Neurosci* 2006; 18: 48–63.
- Butter CM, McDonald JA, Snyder DR. Orality, preference behavior, and reinforcement value of nonfood objects in monkeys with orbital frontal lesions. *Science* 1969; 164: 1306–7.
- Cabeza R, Nyberg L. Imaging cognition II: an empirical review of 275 PET and fMRI studies. *J Cogn Neurosci* 2000; 12: 1–47.
- Calarge C, Andreasen NC, O'Leary DS. Visualizing how one brain understands another: a PET study of theory of mind. *Am J Psychiatry* 2003; 160: 1954–64.
- Calder AJ, Lawrence AD, Keane J, Scott SK, Owen AM, Christoffels I, et al. Reading the mind from eye gaze. *Neuropsychologia* 2002; 40: 1129–38.
- Carr L, Iacoboni M, Dubeau MC, Mazziotta JC, Lenzi GL. Neural mechanisms of empathy in humans: a relay from neural systems for imitation to limbic areas. *Proc Natl Acad Sci* 2003; 100: 5497–502.
- Carran MA, Kohler CG, O'Connor MJ, Bilker WB, Sperling MR. Mania following temporal lobectomy. *Neurology* 2003; 61: 770–4.
- Castelli F, Happe F, Frith U, Frith C. Movement and mind: a functional imaging study of perception and interpretation of complex intentional movement patterns. *Neuroimage* 2000; 12: 314–25.
- Chua P, Krams M, Toni I, Passingham R, Dolan R. A functional anatomy of anticipatory anxiety. *Neuroimage* 1999; 9: 563–71.
- Crespo-Facorro B, Nopoulos PC, Chemerinski E, Kim J-J, Andreasen NC, Magnotta V. Temporal pole morphology and psychopathology in males with schizophrenia. *Psychiatry Res* 2004; 132: 107–15.
- Critchley HD. The human cortex responds to an interoceptive challenge. *Proc Natl Acad Sci USA* 2004; 101: 6333–4.
- Damasio AR, Grabowski TJ, Bechara A, Damasio H, Ponto LL, Parvizi J, et al. Subcortical and cortical brain activity during the feeling of self-generated emotions. *Nat Neurosci* 2000; 3: 1049–56.
- Damasio AR, Tranel D, Damasio H. Face agnosia and the neural substrates of memory. *Annu Rev Neurosci* 1990; 13: 89–109.
- Damasio H, Grabowski TJ, Tranel D, Hichwa RD, Damasio AR. A neural basis for lexical retrieval. *Nature* 1996; 380: 499–505.
- Damasio H, Tranel D, Grabowski T, Adolphs R, Damasio A. Neural systems behind word and concept retrieval. *Cognition* 2004; 92: 179–229.
- Dapretto M, Davies MS, Pfeifer JH, Scott AA, Sigman M, Bookheimer SY, et al. Understanding emotions in others: mirror neuron dysfunction in children with autism spectrum disorders. *Nat Neurosci* 2006; 9: 28–30.
- Desimone R. Face-selective cells in the temporal cortex of monkeys. *J Cogn Neurosci* 1991; 3: 1–8.
- Devlin JT, Russell RP, Davis MH, Price CJ, Wilson J, Moss HE, et al. Susceptibility-induced loss of signal: comparing PET and fMRI on a semantic task. *Neuroimage* 2000; 11: 589–600.
- Dolan RS, Lane R, Chua P, Fletcher P. Dissociable temporal lobe activations during emotional episodic memory retrieval. *Neuroimage* 2000; 11: 203–9.
- Dougherty DD, Shin LM, Alpert NM, Pitmann RK, Orr SP, Lasko M, et al. Anger in healthy men: A PET study using script-driven imagery. *Biol Psychiatry* 1999; 46: 466–72.
- Duvernoy HM. The human brain. Surface, blood supply, and three-dimensional sectional anatomy. New York: Springer Wien; 1999.
- Eugene F, Levesque J, Mensour B, Leroux J-M, Beaudoin G, Bourgouin P, et al. The impact of individual differences on the neural circuitry underlying sadness. *Neuroimage* 2003; 19: 354–64.
- Evans JJ, Heggs AJ, Antoun N, Hodges JR. Progressive prosopagnosia associated with selective right temporal lobe atrophy. A new syndrome? *Brain* 1995; 118: 1–13.
- Farrow TFD, Zheng Y, Wilkinson ID, Spence SA, Deakin JFW, Tarrrier N, et al. Investigating the functional anatomy of empathy and forgiveness. *Neuroreport* 2001; 12: 2433–8.
- Ferstl EC, von Cramon DY. What does the frontomedian cortex contribute to language processing: coherence or theory of mind? *Neuroimage* 2002; 17: 1599–612.
- Fletcher PC, Happe F, Frith U, Baker SC. Other minds in the brain: a functional imaging study of "theory of mind" in story comprehension. *Cognition* 1995; 57: 109–21.
- Franzen EA, Myers RE. Neural control of social behavior: prefrontal and anterior temporal cortex. *Neuropsychologia* 1973; 11: 141–57.
- Frith U. Mind blindness and the brain in autism. *Neuron* 2001; 32: 969–79.
- Frith U, Frith C. Development and neurophysiology of mentalizing. *Phil Trans R Soc Lond B* 2003; 358: 459–73.
- Fukatsu R, Fujii T, Tsukiura T, Yamadori A, Otsuki T. Proper name anomia after left temporal lobectomy: a patient study. *Neurology* 1999; 52: 1096–9.
- Gainotti G, Barbier A, Marra C. Slowly progressive defect in recognition of familiar people in a patient with right anterior temporal atrophy. *Brain* 2003; 126: 792–803.
- Gallagher HL, Happe F, Brunswick N, Fletcher PC, Frith U, Frith CD. Reading the mind in cartoons and stories: an fMRI study of 'theory of mind' in verbal and nonverbal tasks. *Neuropsychologia* 2000; 38: 11–21.
- Gallagher HL, Jack AI, Roepstorff A, Frith CD. Imaging the intentional stance in a competitive game. *Neuroimage* 2002; 16: 814–21.
- Gentileschi V, Sperber S, Spinnler H. Progressive defective recognition of familiar people. *Neurocase* 1999; 5: 407–24.
- Gentileschi V, Sperber S, Spinnler H. Crossmodal agnosia for familiar people as a consequence of right infero-polar temporal atrophy. *Cogn Neuropsychol* 2001; 18: 439–63.
- German TP, Niehaus JL, Roarty MP, Giesbrecht B, Miller MB. Neural correlates of detecting pretense: automatic engagement of the intentional stance under covert conditions. *J Cogn Neurosci* 2004; 16: 1805–17.
- Ghika-Schmid F, Assal G, De Tribolet N, Regli F. Kluver-Bucy syndrome after left anterior temporal resection. *Neuropsychologia* 1995; 33: 101–13.
- Gloor P. The temporal lobe and limbic system. New York: Oxford University Press; 1997.
- Gloor P, Olivier A, Quesney LF, Andermann F, Horowitz S. The role of the limbic system in experiential phenomena of temporal lobe epilepsy. *Ann Neurol* 1982; 12: 129–44.
- Glosser G, Salvucci AE, Chiaravalloti ND. Naming and recognizing famous faces in temporal lobe epilepsy. *Neurology* 2003; 61: 81–6.

- Glosser G, Zvil AS, Glosser DS, O'Connor MM, Sperling MR. Psychiatric aspects of temporal lobe epilepsy before and after anterior temporal lobectomy. *J Neurol Neurosurg Psychiatry* 2000; 68: 53–8.
- Goel V, Grafman J, Sadato N, Hallett M. Modeling other minds. *Neuroreport* 1995; 6: 1741–6.
- Gorno-Tempini ML, Price CJ. Identification of famous faces and buildings: a functional neuroimaging study of semantically unique items. *Brain* 2001; 124: 2087–97.
- Gorno-Tempini ML, Price CJ, Josephs O, Vandenberghe R, Cappa SF, Kapur N, et al. The neural systems sustaining face and proper-name processing. *Brain* 1998; 121: 2103–18.
- Gorno-Tempini ML, Rankin KP, Woolley JD, Rosen HJ, Phengrasamy L, Miller BL. Cognitive and behavioral profile in a case of right anterior temporal lobe neurodegeneration. *Cortex* 2004; 40: 631–44.
- Grabowski TJ, Damasio H, Tranel D, Boles Ponto LL, Hichwa RD, Damasio AR. A role for left temporal pole in the retrieval of words for unique identities. *Hum Brain Mapp* 2001; 13: 199–212.
- Grezes J, Frith C, Passingham RE. Brain mechanisms for inferring deceit in the actions of others. *J Neurosci* 2004; 24: 5500–5.
- Griffiths TD, Buchel C, Frackowiak RSJ, Patterson RD. Analysis of temporal structure in sound by the human brain. *Nat Neurosci* 1998; 1: 422–7.
- Gross CG. Representation of visual stimuli in inferior temporal cortex. *Philos Trans R Soc Lond B* 1992; 335: 3–10.
- Gur RE, Turetsky BI, Cowell PE, Finkelman C, Maany V, Grossman RI, et al. Temporolimbic volume reductions in schizophrenia. *Arch Gen Psychiatry* 2000; 57: 769–75.
- Hadland KA, Rushworth MFS, Gaffan D, Passingham RE. The effect of cingulate lesions on social behaviour and emotion. *Neuropsychologia* 2003; 41: 919–31.
- Hanley JR, Kay J. Proper name anomia and anomia for the names of people: functionally dissociable impairments? *Cortex* 1998; 34: 155–8.
- Heekeren HR, Wartenburger I, Schmidt H, Schwintowski H-P, Villringer A. An fMRI study of simple ethical decision-making. *Neuroreport* 2003; 14: 1215–9.
- Heider F, Simmel M. An experimental study of apparent behaviour. *Am J Psychol* 1944; 57: 243–59.
- Hirstein W, Ramachandran VS. Capgras syndrome: a novel probe for understanding the neural representation of the identity and familiarity of persons. *Proc R Soc Lond Part B: Biol Sci* 1997; 264: 437–44.
- Hodges JR. Frontotemporal dementia (Pick's disease): clinical features and assessment. *Brain* 2001; 56: s6–10.
- Horel JA, Keating EG, Misantone LJ. Partial Klüver-Bucy syndrome produced by destroying temporal neocortex or amygdala. *Brain Res* 1975; 94: 347–59.
- Hudson AJ, Grace GM. Misidentification syndromes related to face specific area in the fusiform gyrus. *J Neurol Neurosurg Psychiatry* 2000; 69: 645–8.
- Iacoboni M, Lieberman MD, Knowlton BJ, Molnar-Szakacs I, Moritz M, Throop CJ, et al. Watching social interactions produces dorsomedial prefrontal and medial parietal BOLD fMRI signal increases compared to a resting baseline. *Neuroimage* 2004; 21: 1167–73.
- Imaizumi S, Mori K, Kiritani S, Kawashima R, Sugiura M, Fukuda H, et al. Vocal identification of speaker and emotion activates different brain regions. *Neuroreport* 1997; 8: 2809–12.
- Insausti R, Amaral DG, Cowan WM. The entorhinal cortex of the monkey: II. Cortical afferents. *J Comp Neurol* 1987a; 264: 356–95.
- Insausti R, Amaral DG, Cowan WM. The entorhinal cortex of the monkey: III. Subcortical afferents. *J Comp Neurol* 1987b; 264: 396–408.
- Insausti R, Juottonen K, Soininen H, Insausti A, Partanen K, Vainio P, et al. MR volumetric analysis of the human entorhinal, perirhinal, and temporopolar cortices. *AJNR Am J Neuroradiol* 1998; 19: 659–71.
- Jorge ER, Robinson RG, Starkstein SE, Arndt SV, Forrester AW, Weisler FH. Secondary mania following traumatic brain injury. *Am J Psychiatry* 1993; 150: 916–21.
- Joubert S, Felician O, Barbeau E, Sontheimer A, Barton JJ, Ceccaldi M, et al. Impaired configurational processing in a case of progressive prosopagnosia associated with predominant right temporal lobe atrophy. *Brain* 2003; 126: 2537–50.
- Kanwisher N, McDermott J, Chun MM. The fusiform face area: a module in human extrastriate cortex specialized for face perception. *J Neurosci* 1997; 17: 4302–11.
- Kasai K, Shenton ME, Salisbury DF, Onitsuka T, Toner SK, Yurgelun-Todd D, et al. Differences and similarities in insular and temporal pole MRI gray matter volume abnormalities in first-episode schizophrenia and affective psychosis. *Arch Gen Psychiatry* 2003; 60: 1069–77.
- Kim J-W, Kim J-J, Jeong BS, Ki SW, Im D-M, Lee SJ, et al. Neural mechanism for judging the appropriateness of facial affect. *Cogn Brain Res* 2005; 25: 659–67.
- Kimbrell TA, George MS, Parakh PI, Ketter TA, Podell DM, Danielson AL, et al. Regional brain activity during transient self-induced anxiety and anger in healthy adults. *Biol Psychiatry* 1999; 46: 454–65.
- Kling AS, Steklis HD. A neural substrate for affiliative behavior in nonhuman primates. *Brain Behav Evol* 1976; 13: 216–38.
- Kling AS, Tachiki K, Lloyd R. Neurochemical correlates of the Klüver-Bucy syndrome by in vivo microdialysis in monkey. *Behav Brain Res* 1993; 56: 161–70.
- Klüver H, Bucy P. Preliminary analysis of functions of the temporal lobes in monkeys. *Arch Neurol Psychiatry* 1939; 41: 979–1000.
- Koelsch S, Gunter TC, von Cramon DY, Zysset S, Lohmann G, Friederici AD. Bach speaks: a cortical “language-network” serves the processing of music. *Neuroimage* 2002; 17: 956–66.
- Kondo H, Saleem KS, Price JL. Differential connections of the temporal pole with the orbital and medial prefrontal networks in macaque monkeys. *J Comp Neurol* 2003; 465: 499–523.
- Kondo H, Saleem KS, Price JL. Differential connections of the perirhinal and parahippocampal cortex with the orbital and medial prefrontal networks in macaque monkeys. *J Comp Neurol* 2005; 493: 479–509.
- Lane RD, Fink GR, Chau PML, Dolan RJ. Neural activation during selective attention to subjective emotional responses. *Neuroreport* 1997a; 8: 3969–72.
- Lane RD, Reiman EM, Ahern GL, Schwartz GE, Davidson RJ. Neuroanatomical correlates of happiness, sadness, and disgust. *Am J Psychiatry* 1997b; 154: 926–33.
- Leveroni CL, Seidenberg M, Mayer AR, Mead LA, Binder JR, Rao SM. Neural systems underlying the recognition of familiar and newly learned faces. *J Neurosci* 2000; 20: 878–86.
- Levesque J, Eugene F, Joannette Y, Paquette V, Mensour B, Beaudoin G, et al. Neural circuitry underlying voluntary suppression of sadness. *Biol Psychiatry* 2003; 53: 502–10.
- Lilly R, Cummings JL, Benson F, Frankel M. The human Klüver-Bucy syndrome. *Neurology* 1983; 33: 1141–45.
- Lipson SE, Sacks O, Devinsky O. Selective emotional detachment from family after right temporal lobectomy. *Epilepsy Behav* 2003; 4: 340–2.
- Lorberbaum JP, Newman JD, Horwitz AR, Dubno JR, Lydiard RB, Hamner MB, et al. A potential role for thalamocingulate circuitry in human maternal behavior. *Biol Psychiatry* 2002; 51: 431–45.
- Markowitsch HJ. Which brain regions are critically involved in episodic memory? *Brain Res Rev* 1995; 21: 117–27.
- McCabe K, Houser D, Ryan L, Smith V, Trouard T. A functional imaging study of cooperation in two-person reciprocal exchange. *Proc Natl Acad Sci* 2001; 98: 11832–5.
- McCarthy RA, Warrington EK. Actors but not scripts: the dissociation of people and events in retrograde amnesia. *Neuropsychologia* 1992; 30: 633–44.
- Mesulam MM. Paralimbic (mesocortical) areas. In: Mesulam MM, editor. *Principles of behavioral and cognitive neurology*. New York: Oxford University Press; 2000. p. 49–54.
- Miller BL, Boone K, Cummings JL, Read SL, Mishkin F. Functional correlates of musical and visual ability in frontotemporal dementia. *Br J Psychiatry* 2000; 176: 458–63.

- Miller BL, Cummings J, Mishkin F, Boone K, Prince F, Ponton M, et al. Emergence of artistic talent in fronto-temporal dementia. *Neurology* 1998; 51: 978–82.
- Miller BL, Darby AL, Benson DF, Cummings JL, Miller MH. Aggressive, socially disruptive and antisocial behaviour associated with fronto-temporal dementia. *Br J Psychiatry* 1997; 170: 150–5.
- Miller BL, Darby AL, Swartz JR, Yener GG, Mena I. Dietary changes, compulsions, and sexual behavior in frontotemporal degeneration. *Dementia* 1995; 6: 195–9.
- Miller LA, Taber KH, Gabbard GO, Hurley RA. Neural underpinnings of fear and its modulation: implications for anxiety disorders. *J Neuropsychiatry Clin Neurosci* 2005; 17: 1–6.
- Mitchell JP, Macrae CN, Banaji MR. Dissociable medial prefrontal contributions to judgments of similar and dissimilar others. *Neuron* 2006; 50: 655–63.
- Mobbs D, Greicius MD, Abdel-Aziz E, Menon V, Reiss AL. Humor modulates the mesolimbic reward centers. *Neuron* 2003; 40: 1041–8.
- Moll J, de Oliveira-Souza R, Bramati IE, Grafman J. Functional networks in emotional moral and nonmoral social judgments. *Neuroimage* 2002a; 16: 696–703.
- Moll J, de Oliveira-Souza R, Eslinger PJ, Bramati IE, Mourao-Miranda J, Andreiuolo PA, et al. The neural correlates of moral sensitivity: a functional magnetic resonance imaging investigation of basic and moral emotions. *J Neurosci* 2002b; 22: 2730–6.
- Moriguchi Y, Ohnishi T, Lane RD, Maeda M, Mori T, Nemoto K, et al. Impaired self-awareness and theory of mind: an fMRI study of mentalizing in alexithymia. *Neuroimage* 2006; 32: 1472–82.
- Moss HE, Rodd JM, Stamatakis EA, Bright P, Tyler LK. Anteromedial temporal cortex supports fine-grained differentiation among objects. *Cereb Cortex* 2005; 15: 616–27.
- Mummery CJ, Patterson K, Price CJ, Ashburner J, Frackowiak RSJ, Hodges JR. A voxel-based morphometry study of semantic dementia: relationship between temporal lobe atrophy and semantic memory. *Ann Neurol* 2000; 47: 36–45.
- Murai T, Fujimoto S. Rapid cycling bipolar disorder after temporal polar damage. *Brain Injury* 2003; 17: 355–8.
- Mychack P, Kramer JH, Boone KB, Miller BL. The influence of right frontotemporal dysfunction on social behavior in frontotemporal dementia. *Neurology* 2001; 56: 11–5.
- Myers RE. Discussion of 'outlines of anid and felid brain evolution'. *Ann NY Acad Sci* 1969; 167: 289–92.
- Myers RE. Neurology of social behavior and affect in primates: a study of prefrontal and anterior temporal cortex. In: Zulch KJ, Creutzfeldt O, Galbraith GC, editors. *Cerebral localization New York/Heidelberg/Berlin: Springer-Verlag; 1975. p. 161–70.*
- Myers RE, Swett C. Social behavior deficits of free-ranging monkeys after anterior temporal cortex removal: a preliminary report. *Brain Res* 1970; 18: 551–6.
- Nakamura K, Kawashima R, Sato N, Nakamura A, Sugiura M, Kato T, et al. Functional delineation of the human occipito-temporal areas related to face and scene processing: a PET study. *Brain* 2000; 123: 1903–12.
- Nakamura K, Kubota K. The primate temporal pole: its putative role in object recognition and memory. *Behav Brain Res* 1996; 77: 53–77.
- Nakamura K, Matsumoto K, Mikami A, Kubota K. Visual response properties of single neurons in the temporal pole of behaving monkeys. *J Neurophysiol* 1994; 71: 1206–21.
- Ohnishi T, Moriguchi Y, Matsuda H, Mori T, Hirakata M, Imabayashi E, et al. The neural network for the mirror system and mentalizing in normally developed children: an fMRI study. *Neuroreport* 2004; 15: 1483–7.
- Ong WY, Garey LJ. Ultrastructural features of biopsied temporopolar cortex (area 38) in a case of schizophrenia. *Schizophrenia Res* 1993; 10: 15–27.
- Parsons LM, Sergent J, Hodges DA, Fox PT. The brain basis of piano performance. *Neuropsychologia* 2005; 43: 199–215.
- Perrett DI, Smith PA, Potter DD, Mistlin AJ, Head AS, Milner AD, et al. Visual cells in the temporal cortex sensitive to face view and gaze direction. *Proc R Soc B: Biol Sci* 1985; 223: 293–317.
- Phillips ML, Young AW, Scott SK, Calder AJ, Andrew C, Giampietro V, et al. Neural responses to facial and vocal expressions of fear and disgust. *Proc R Soc B: Biol Sci* 1998; 265: 1809–17.
- Platel H. Functional neuroimaging of semantic and episodic musical memory. *Ann NY Acad Sci* 2005; 1060: 136–47.
- Poeck K, Pilleri G. Release of hypersexual behavior due to lesion in the limbic system. *Acta Neurol Scand* 1965; 41: 233–44.
- Poremba A, Saunders RC, Crane AM, Cook M, Sokoloff L, Mishkin M. Functional mapping of the primate auditory system. *Science* 2003; 299: 568–72.
- Pourtois G, Schwartz S, Seghier ML, Lazeyras F, Vuilleumier P. View-independent coding of face identity in frontal and temporal cortices is modulated by familiarity: an event-related fMRI study. *Neuroimage* 2005; 24: 1214–24.
- Puce A, Perrett D. Electrophysiology and brain imaging of biological motion. *Philos Trans R Soc Lond B Biol Sci* 2003; 358: 435–45.
- Rankin KP, Gorno-Tempini ML, Allison SC, Stanley CM, Glenn S, Weiner MW, et al. Structural anatomy of empathy in neurodegenerative disease. *Brain* 2006; 129: 2945–56.
- Rankin KP, Kramer JH, Mychack P, Miller BL. Double dissociation of social functioning in frontotemporal dementia. *Neurology* 2003; 60: 266–71.
- Ranote S, Elliott R, Abel KM, Mitchell R, Deakin JFW, Appleby L. The neural basis of maternal responsiveness to infants: an fMRI study. *Neuroreport* 2004; 15: 1825–9.
- Redoute J, Stoleru S, Gregoire M-C, Costes N, Cinotti L, Lavenne F, et al. Brain processing of visual sexual stimuli in human males. *Hum Brain Mapp* 2000; 11: 162–77.
- Reiman EM, Fussellmann MJ, Fox PT, Raichle ME. Neuroanatomical correlates of anticipatory anxiety. *Science* 1989; 243: 1071–4.
- Rilling JK, Sanfey AG, Aronson JA, Nystrom LE, Cohen JD. The neural correlates of theory of mind within interpersonal interactions. *Neuroimage* 2004; 22: 1694–703.
- Rothstein P, Henson RNA, Treves A, Driver J, Dolan RJ. Morphing Marilyn into Maggie dissociates physical and identity face representations in the brain. *Nature Neurosci* 2005; 8: 107–13.
- Royet J-P, Zald D, Versace R, Costes N, Lavenne F, Koenig O, et al. Emotional responses to pleasant and unpleasant olfactory, visual, and auditory stimuli: a positron emission tomography study. *J Neurosci* 2000; 20: 7752–9.
- Satoh M, Takeda K, Nagata K, Shimosegawa E, Kuzuhara S. Positron-emission tomography of brain regions activated by recognition of familiar music. *Am J Neuroradiol* 2006; 27: 1101–6.
- Saxe R, Powell LJ. It's the thought that counts: specific brain regions for one component of theory of mind. *Psychol Sci* 2006; 17: 692–9.
- Schultz RT, Grelotti DJ, Klin A, Kleinman J, Van der Gaag C, Marois R, et al. The role of the fusiform face area in social cognition: implications for the pathobiology of autism. *Philos Trans R Soc Lond Ser B-Biol Sci* 2003; 358: 415–27.
- Sellal F, Kahane P, Andreantseheno M, Vercueil L, Pellat J, Hirsch E. Dramatic changes in artistic preference after left temporal lobectomy. *Epilepsy Behav* 2003; 4: 449–50.
- Sergent J, Ohta S, Macdonald B. Functional neuroanatomy of face and object processing: a Positron Emission Tomography Study. *Brain* 1992; 115: 15–36.
- Sergent J, Signoret J. Functional and anatomical decomposition of face processing: evidence from prosopagnosia and PET study of normal subjects. *Philos Trans R Soc Lond: Biol Sci* 1992; 335: 55–62.
- Shaw P, Lawrence EJ, Radbourne C, Bramham J, Polkey CE, David AS. The impact of early and late damage to the human amygdala on "theory of mind" reasoning. *Brain* 2004; 127: 1535–48.
- Shin LM, Dougherty DD, Orr SP, Pitman RK, Lasko M, Macklin ML, et al. Activation of anterior paralimbic structures during guilt-related script-driven imagery. *Biol Psychiatry* 2000; 48: 43–50.

- Snowden JS, Thompson JC, Neary D. Knowledge of famous faces and names in semantic dementia. *Brain* 2004; 127: 860–72.
- Stefanacci L, Suzuki W, Amaral D. Organization of connections between the amygdaloid complex and the perirhinal and parahippocampal cortices in macaque monkeys. *J Comp Neurol* 1996; 375: 552–82.
- Sugiura M, Kawashima R, Nakamura K, Sato N, Nakamura A, Kato T, et al. Activation reduction in anterior temporal cortices during repeated recognition of faces of personal acquaintances. *Neuroimage* 2001; 13: 877–90.
- Suzuki WA, Amaral DG. Perirhinal and parahippocampal cortices of the macaque monkey: cortical afferents. *J Comp Neurol* 1994; 350: 497–533.
- Thompson SA, Patterson K, Hodges JR. Left/right asymmetry of atrophy in semantic dementia: behavioral-cognitive implications. *Neurology* 2003; 61: 1196–203.
- Tippett LJ, Miller LA, Farah MJ. Prosopamnesia: a selective impairment in face learning. *Cogn Neuropsychol* 2000; 17: 241–55.
- Tranel D. Impaired naming of unique landmarks is associated with left temporal polar damage. *Neuropsychology* 2006; 20: 1–10.
- Tsukiura T, Fujii T, Fukatsu R, Otsuki T, Okuda J, Umetsu A, et al. Neural basis of the retrieval of people's names: evidence from brain-damaged patients and fMRI. *J Cogn Neurosci* 2002; 14: 922–37.
- Tsukiura T, Mochizuki-Kawai H, Fujii T. Dissociable roles of the bilateral anterior temporal lobe in face-name associations: an event-related fMRI study. *Neuroimage* 2006; 30: 617–26.
- Tsukiura T, Namiki M, Fujii T, Iijima T. Time-dependent neural activations related to recognition of people's names in emotional and neutral face-name associative learning: an fMRI study. *Neuroimage* 2003; 20: 784–94.
- Tyler LK, Stamatakis EA, Bright P, Acres K, Abdallah S, Rodd JM, et al. Processing objects at different levels of specificity. *J Cogn Neurosci* 2004; 16: 351–62.
- Vaina LM, Solomon J, Chowdhury S, Sinha P, Belliveau JW. Functional neuroanatomy of biological motion perception in humans. *Proc Natl Acad Sci USA* 2001; 98: 11656–61.
- Vogele K, Busfeld P, Newen A, Herrmann S, Happe F, Falkai P, et al. Mind reading: neural mechanisms of theory of mind and self-perspective. *Neuroimage* 2001; 14: 170–81.
- Vollm BA, Taylor ANW, Richardson P, Rhiannon C, Stirling J, McKie S, et al. Neuronal correlates of theory of mind and empathy: a functional magnetic resonance imaging study in a nonverbal task. *Neuroimage* 2006; 29: 90–8.
- Walter H, Adenzato M, Ciaramidaro A, Enrici I, Pia L, Bara BG. Understanding intentions in social interaction: the role of the anterior paracingulate cortex. *J Cogn Neurosci* 2004; 16: 1854–63.
- Warren JD, Griffiths TD. Distinct mechanisms for processing spatial sequences and pitch sequences in the human auditory brain. *J Neurosci* 2003; 23: 5799–804.
- Zatorre RJ, Belin P. Spectral and temporal processing in human auditory cortex. *Cereb Cortex* 2001; 11: 946–53.

## Appendix A

To select the studies used to create Fig. 2A, we prepared a list of published fMRI and PET studies found through an

electronic search within psycinfo and pubmed databases. Search terms were: temporal pole, ba 38, anterior temporal lobe, planum polare, area TG, perirhinal cortex or paralimbic cortex. Then, we excluded publications that: (1) were not peer-reviewed, (2) studied special populations such as elderly or abnormal populations, (3) did not mention Talairach or MNI coordinates or (4) did not present material auditorily or visually. Studies that were included in the final list varied with regard to the type of stimulus and the type of test. These studies were: Sergent *et al.*, 1992; Damasio *et al.*, 1996; Imaizumi *et al.*, 1997; Lane *et al.*, 1997a, b; Gorno-Tempini *et al.*, 1998; Griffiths *et al.*, 1998; Phillips *et al.*, 1998; Blair *et al.*, 1999; Kimbrell *et al.*, 1999; Dougherty *et al.*, 1999; Brunet *et al.*, 2000; Castelli *et al.*, 2000; Dolan *et al.*, 2000; Gallagher *et al.*, 2000; Leveroni *et al.*, 2000; Nakamura *et al.*, 2000; Royet *et al.*, 2000; Shin *et al.*, 2000; Beauregard *et al.*, 2001; Farrow *et al.*, 2001; Gorno-Tempini and Price, 2001; Grabowski *et al.*, 2001; Zatorre and Belin, 2001; Vaina *et al.*, 2001; Berthoz *et al.*, 2002; Koelsch *et al.*, 2002; Lorberbaum *et al.*, 2002; Moll *et al.*, 2002b; Tsukiura *et al.*, 2002; Eugene *et al.*, 2003; Heekeren *et al.*, 2003; Levesque *et al.*, 2003; Schultz *et al.*, 2003; Tsukiura *et al.*, 2003; Warren and Griffiths, 2003; Brown *et al.*, 2004; Grezes *et al.*, 2004; Ranote *et al.*, 2004; Tyler *et al.*, 2004; Kim *et al.*, 2005; Moss *et al.*, 2005; Parsons *et al.*, 2005; Platel, 2005; Pourtois *et al.*, 2005; Rothstein *et al.*, 2005; Satoh *et al.*, 2006; and Tsukiura *et al.*, 2006.

## Appendix B

Studies used to create Fig. 2B were a subset of those used in Fig. 2A that manipulated emotion or theory of mind. These studies were: Fletcher *et al.*, 1995; Lane *et al.*, 1997a, b; Phillips *et al.*, 1998; Blair *et al.*, 1999; Dougherty *et al.*, 1999; Kimbrell *et al.*, 1999; Brunet *et al.*, 2000; Castelli *et al.*, 2000; Dolan *et al.*, 2000; Gallagher *et al.*, 2000; Royet *et al.*, 2000; Shin *et al.*, 2000; Beauregard *et al.*, 2001; Farrow *et al.*, 2001; Vaina *et al.*, 2001; Vogele *et al.*, 2001; Berthoz *et al.*, 2002; Lorberbaum *et al.*, 2002; Moll *et al.*, 2002a, b; Eugene *et al.*, 2003; Heekeren *et al.*, 2003; Levesque *et al.*, 2003; Schultz *et al.*, 2003; Tsukiura *et al.*, 2003; Ranote *et al.*, 2004; Grezes *et al.*, 2004; and Kim *et al.*, 2005.